

Long-Term 3-Dimensional Stability of Mandibular Advancement Surgery

Alexandre A. Franco, DDS, MS, PhD, * Lucia Helena S. Cevidanes, DDS, MS, PhD, †
 Ceib Phillips, BS, MPH, PhD, ‡ Paul Emile Rossouw, DDS, MS, PhD, §
 Timothy A. Turvey, DDS, || Felipe de Assis R. Carvalho, DDS, MS, PhD, ¶
 Leonardo K. de Paula, DDS, MS, # Cátia Cardoso A. Quintão, DDS, MS, PhD, **
 and Marco Antonio O. Almeida, DDS, MS, PhD ††

Purpose: To evaluate 3-dimensional changes in the position of the condyles, rami, and chin from 1 to 3 years after mandibular advancement surgery.

Materials and Methods: This prospective observational study used pre- and postoperative cone-beam computed tomograms of 27 subjects with skeletal Class II jaw relation and normal or deep overbite. An automatic technique of cranial base superimposition was used to assess positional and bone remodeling changes that were visually displayed and quantified using 3-dimensional color maps. Analysis of covariance with presence of genioplasty, age at time of surgery, and gender as explanatory variables was used to estimate and test adjusted mean changes for each region of interest.

Results: The chin rotated downward and backward 1 to 3 years after surgery. Changes of at least 2 mm were observed in 17% of cases. Mandibular condyles presented with displacements or bone remodeling of at least 2 mm on the anterior surface (21% of cases on the left side and 13% on the right), superior surface (8% on right and left sides), and lateral poles (17% on left side and 4% on right). Posterior borders of the rami exhibited symmetric lateral or rotational displacements in 4% of cases.

Conclusion: In the hierarchy of surgical stability, mandibular advancement surgery is considered one of the most stable surgical procedures. However, 1 to 3 years after surgery, approximately 20% of patients had 2- to 4-mm changes in horizontal and vertical chin positions or changes in condylar position and adaptive bone remodeling.

© 2013 American Association of Oral and Maxillofacial Surgeons
J Oral Maxillofac Surg ■ :e1-e10, 2013

The construction of virtual 3-dimensional (3D) craniofacial surface models of patients has recently allowed the scientific investigation of bone remodeling that leads to morphologic changes. Registration of craniofacial surface models enables the quantification and localization

of changes related to orthodontic and surgical protocols in the treatment of dentofacial disharmonies not readily apparent on 2-dimensional films.¹

Over the past half century, orthosurgical treatment has been used routinely to address maxillary and

*PhD Student, Department of Orthodontics, School of Dentistry, State University of Rio de Janeiro, Rio de Janeiro, Brazil.

†Assistant Professor, Department of Orthodontics, School of Dentistry, University of Michigan, Ann Arbor, MI.

‡Professor, Department of Orthodontics, University of North Carolina, School of Dentistry, Chapel Hill, NC.

§Professor, Department of Orthodontics, University of North Carolina, School of Dentistry, Chapel Hill, NC.

||Professor, Department of Oral and Maxillofacial Surgery, University of North Carolina, School of Dentistry, Chapel Hill, NC.

¶Assistant Professor, Department of Orthodontics, School of Dentistry, State University of Rio de Janeiro, Rio de Janeiro, Brazil.

#Second Year Resident, Department of Orthodontics, Federal University of Rio de Janeiro, School of Dentistry, Rio de Janeiro, Brazil.

**Professor, Department of Orthodontics, School of Dentistry, State University of Rio de Janeiro, Rio de Janeiro, Brazil.

††Professor, Department of Orthodontics, School of Dentistry, State University of Rio de Janeiro, Rio de Janeiro, Brazil.

Address correspondence and reprint requests to Dr Cevidanes: Department of Orthodontics and Pediatric Dentistry, University of Michigan, 2518 Dent, Ann Arbor, MI 48109-1078; e-mail: maluthan@gmail.com

© 2013 American Association of Oral and Maxillofacial Surgeons
 0278-2391/13/00407-2\$36.00/0

<http://dx.doi.org/10.1016/j.joms.2013.04.006>

mandibular discrepancies at skeletal maturity. Since the late 1950s,^{2,6} the stability of orthognathic surgery procedures has been well documented using 2-dimensional cephalometry, and mandibular advancement surgery has been reported to be one of the most stable surgical procedures.⁶ Recent short-term studies, using cone-beam computed tomographic (CBCT) imaging for 3D analysis of cranial and facial hard⁷⁻¹⁰ and soft¹¹ tissues, have described the regional remodeling that occurs in the first year after surgery.

Although previous studies have quantified surgical displacements and short-term adaptation after mandibular advancement, an assessment of long-term results is important.^{12,13} The purpose of this study was to analyze long-term 3D alterations in the rami, condyles, and chin 1 to 3 years after surgery in patients treated with mandibular advancement.

Materials and Methods

The sample in this observational prospective study was comprised of 27 patients (18 female and 9 male) with an average age of 26.7 ± 13.2 years who received orthodontic treatment in preparation for mandibular advancement surgery. All mandibular advancement surgeries were performed using bilateral sagittal split osteotomy and rigid fixation with plates and screws.^{14,15} All patients underwent surgery at the University of North Carolina Memorial Hospital (Chapel Hill, NC) by a surgeon and assisting resident from the Department of Oral and Maxillofacial Surgery. The inclusion criteria consisted of presurgical Class II skeletal malocclusions with mandibular deficiency, 5-mm minimum overjet before surgery, and normal or increased overbite. The exclusion criteria were excessive anterior facial height, anterior open bite, and skeletal deformities from trauma, cleft lip and palate, and syndromic or degenerative conditions, such as rheumatoid arthritis. The research protocol was approved by the biomedical institutional review board, and all participants signed an informed consent form.

CBCT scans were obtained before surgery, 1 year after surgery, and 3 years after surgery with the NewTom 3G scanner (Aperio Services, Sarasota, FL). The imaging protocol involved a 36-second head exposure for a field of view corresponding to a 12-inch field of view. The patients maintained centric occlusion during the scan by biting on a wax bite. A trained radiology technician supervised the procedure.

Segmentation of images of anatomic structures of interest and 3D model construction were performed using the ITK-SNAP open-source software (<http://www.itksnap.org>).¹⁶ The 3D models were constructed from CBCT images with a voxel dimension of $0.5 \times 0.5 \times 0.5$ mm. These virtual models included

the cranial base, maxilla, and mandible (right and left condyles, right and left rami, body, and symphysis; Fig 1). A fully automated registration method for superimposition of the models was performed with IMAGINE open-source software (<http://www.ia.unc.edu/dev/download/Imagine/index.htm>), which compares 2 images using the intensity of the gray scale for each voxel on the cranial base because this structure is not altered by surgery.^{8,17} The presurgical cranial base was used as a reference for the superimposition of 1-year and 3-year postsurgical images (Fig 2).

After the registration steps, all reoriented virtual models, originally saved in an open-source image file format (Guy's Image Processing Lab format), were converted to a 3D interchange file format (Open Inventor File format). This allowed quantitative evaluation of the greatest surface displacement by CMF application software (developed at the M.E. Müller Institute for Surgical Technology and Biomechanics, University of Bern, Bern, Switzerland, under the funding of the Co-Me network; <http://co-me.ch>).¹⁸

CMF software calculates thousands of color-coded point-to-point comparisons (surface distances in millimeters) between presurgical and 1-year postsurgical surface models (before to 1 year after surgery) and between 1-year and 3-year postsurgical models (1 to 3 years after surgery, long-term surgical stability; Figs 3 through 5), so that the difference between the 2 surfaces at any location can be quantified.⁸ For a quantitative assessment of changes between the 3D surface models, the isoline tool was used. It allows the user to define a surface-distance value that is expressed as a contour line (isoline) that corresponds to regions having a surface distance equal to or greater than the defined value. The isoline tool was used to quantitatively measure the greatest displacements between points on the 3D surface models (in millimeters) at 14 specific anatomic areas: right and left posterior condylar surfaces, right and left medial condylar poles, right and left anterior condylar surfaces, right and left lateral condylar poles, right and left superior condylar surfaces, right and left posterior ramus borders, anterior surface of the chin, and inferior border of the chin (Table 1). The condylar lateral and medial poles were defined as tangents to the condylar neck, and the superior surface was defined as the articular surface separating the anterior from the posterior condylar surfaces. The chin surfaces were limited bilaterally by tangents to the long axis of the canines.

Between overlaid structures, the color-coded maps and isolines indicated inward displacement as blue and a negative value and outward displacement as red and a positive value (Fig 3). An absence of change (0 mm) was indicated by green. Displacements in the same direction are shown in different colors depending on the anatomic region.¹ For example, displacements

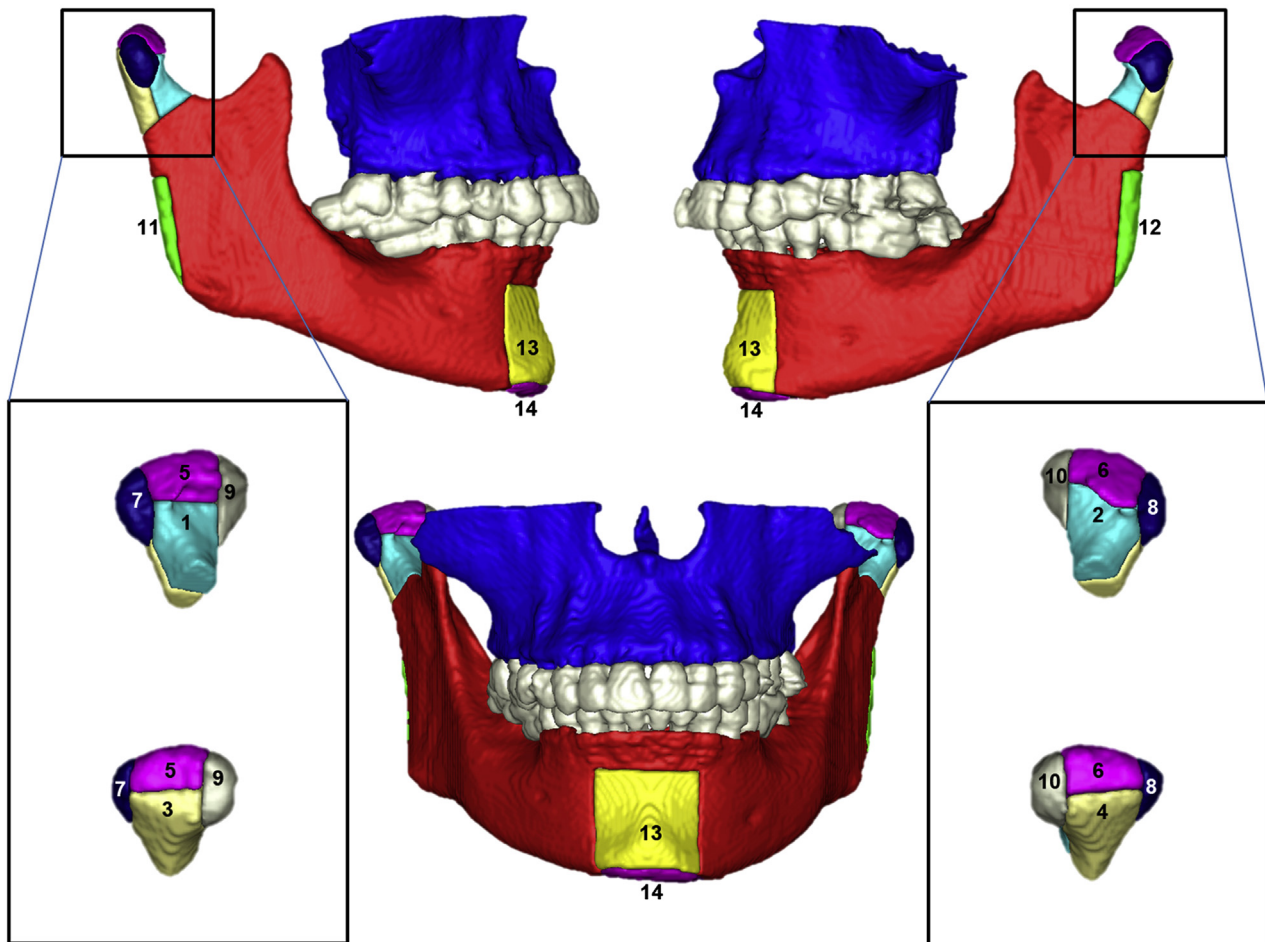


FIGURE 1. Anatomic regions of interest. 1, Right condyle anterior surface; 2, left condyle anterior surface; 3, right condyle posterior surface; 4, left condyle posterior surface; 5, right condyle superior surface; 6, left condyle superior surface; 7, right condyle lateral pole; 8, left condyle lateral pole; 9, right condyle medial pole; 10, left condyle medial pole; 11, right posterior border of ramus; 12, left posterior border of ramus; 13, anterior surface of chin; 14, inferior border of mandible.

Franco et al. Long-Term Stability of Mandibular Advancement. J Oral Maxillofac Surg 2013.

in an anterior direction are displayed as red positive values on the anterior surface of the chin and on the anterior surface of the condyles and as blue negative values on the posterior surface of the ramus and the condyles. Displacements in a posterior direction are displayed as blue negative values on the anterior surface of the chin and on the anterior surface of the con-

dyles and as red positive values on the posterior surface of the ramus and the condyles. For the inferior border of the mandible, positive values represent an inferior displacement and negative values superior displacement. Owing to the adaptive capacity of the condyles, red positive values represent displacement or bone apposition and blue negative values indicate

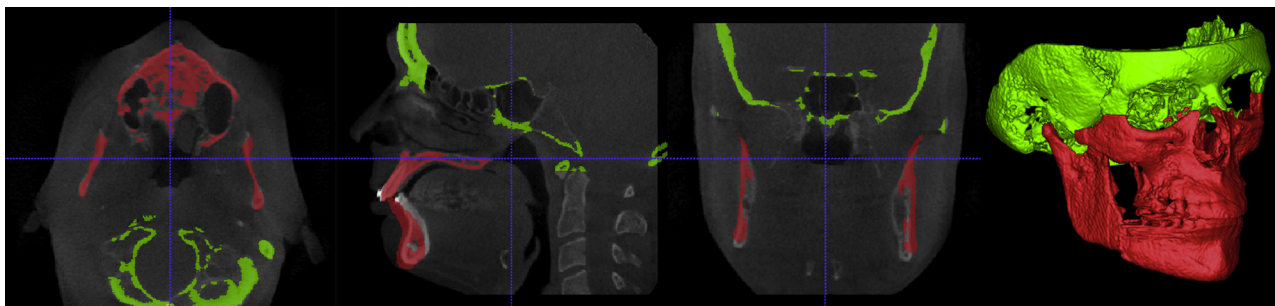


FIGURE 2. Example of the result of superimposition on the cranial base displays the presurgical image (gray) and the surface model 1 year after surgery (red). Note the registration in the cranial base in the 3 planes of space (green).

Franco et al. Long-Term Stability of Mandibular Advancement. J Oral Maxillofac Surg 2013.

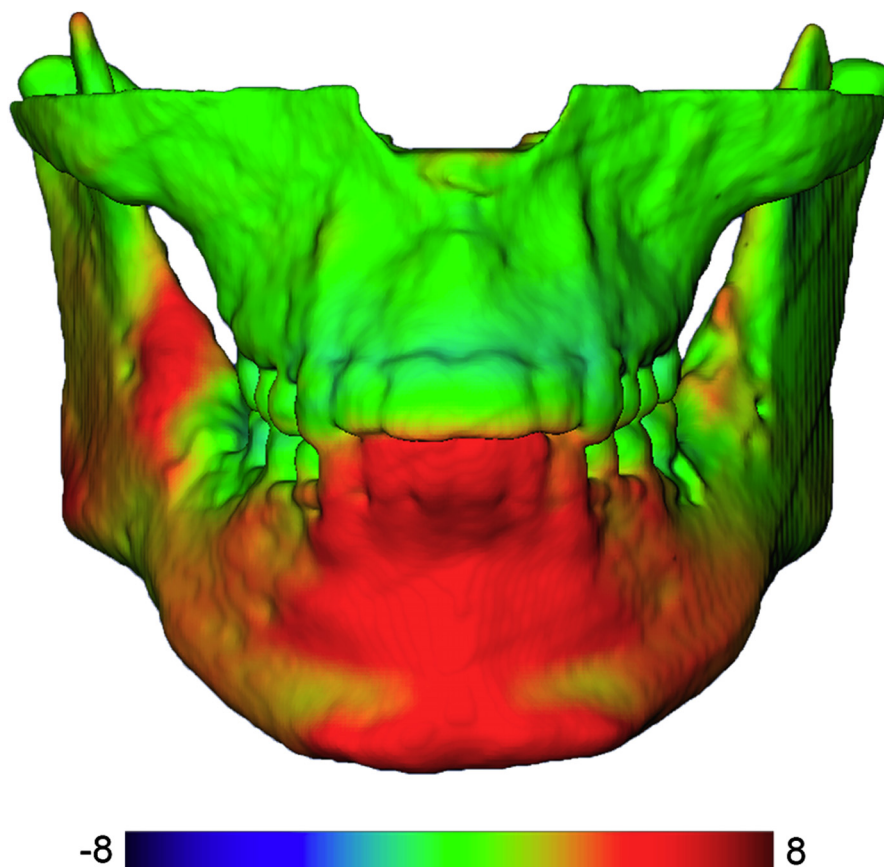


FIGURE 3. Color-coded map of surface distances from before surgery to 1 year after mandibular advancement surgery. The virtual surface models were registered at the cranial base. *Red* represents anterior displacement of the chin and inferior displacement of the inferior border of the mandible (color-coded scale of -8 to $+8$ mm); *green* represents anatomic regions that did not present changes with treatment.

Franco et al. Long-Term Stability of Mandibular Advancement. J Oral Maxillofac Surg 2013.

displacement or bone resorption. Semitransparent overlays were used for the visualization of the location and direction of skeletal displacements or bone remodeling, with a model in an opaque view superimposed onto another partially transparent view (Figs 6-9).

STATISTICAL ANALYSIS

The reproducibility of the method was tested in 10 randomly selected superimpositions. The greatest displacement in each area was measured twice at 15-day intervals; agreement between the repeated measurements was assessed using intraclass correlation.

Analysis of covariance was performed for each anatomic area, considering the presence of genioplasty, age at time of surgery, and gender as explanatory variables, to estimate and test whether the average adjusted change from 1 to 3 years after surgery was 0. The level of significance was set at .05. The percentage of patients who exhibited positive or negative displacement greater than 2 mm at each region was calculated.

Results

Agreement between repeated measurements using the isoline tool was excellent, with intraclass correlations above 0.99 for all measurements of anatomic areas of interest.

Two thirds of subjects were female (67%). Forty percent of subjects had a genioplasty. Follow-ups were 1.1 ± 0.2 years for 1 year after surgery and 3.4 ± 0.4 years for 1 to 3 years after surgery. Average changes from before surgery to 1 year after surgery were smallest on the posterior border of the ramus and on the medial poles of the condyle. As expected, average displacement was largest for the chin (Table 1). On average, changes smaller than 0.5 mm 1 to 3 years after surgery occurred in almost all anatomic regions, and the average changes were -0.1 ± 0.8 mm for overbite and -0.5 ± 0.9 mm for overjet. The largest average changes occurred on the anterior and inferior surfaces of the chin (Table 1) even after adjusting for the presence of a genioplasty, age at time of surgery, and gender (Table 2). The small adjusted mean alterations observed in 13 of the 14

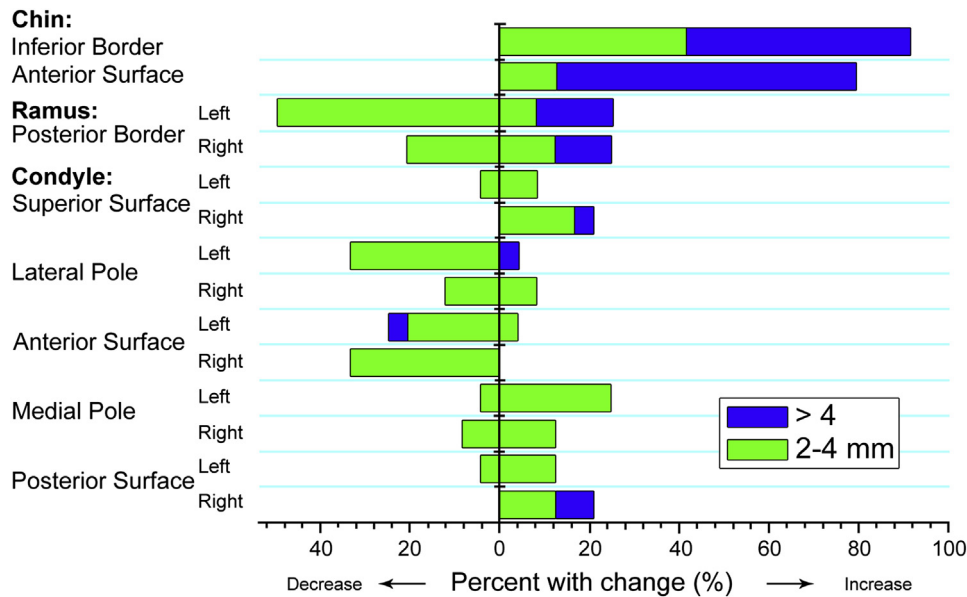


FIGURE 4. Percentage of patients with changes greater than 2 mm or less than -2 mm for each anatomic region of interest from before to 1 year after surgery. Patients with displacements of -2 to 2 mm are not represented. Positive or negative values of displacements represent different directional movements, depending on the specific region of interest. An *increase* was defined as anterior displacement for the anterior surface of the chin and anterior surface of the condyles but as posterior displacement for the posterior surface of the ramus and condyles and as inferior displacement of the inferior border of the chin. A *decrease* was defined as anterior displacement of the posterior surface of the ramus and condyles, as posterior displacement on the anterior surface of the chin and anterior surface of the condyles, and as superior displacement of the inferior border of the mandible.

Franco et al. Long-Term Stability of Mandibular Advancement. *J Oral Maxillofac Surg* 2013.

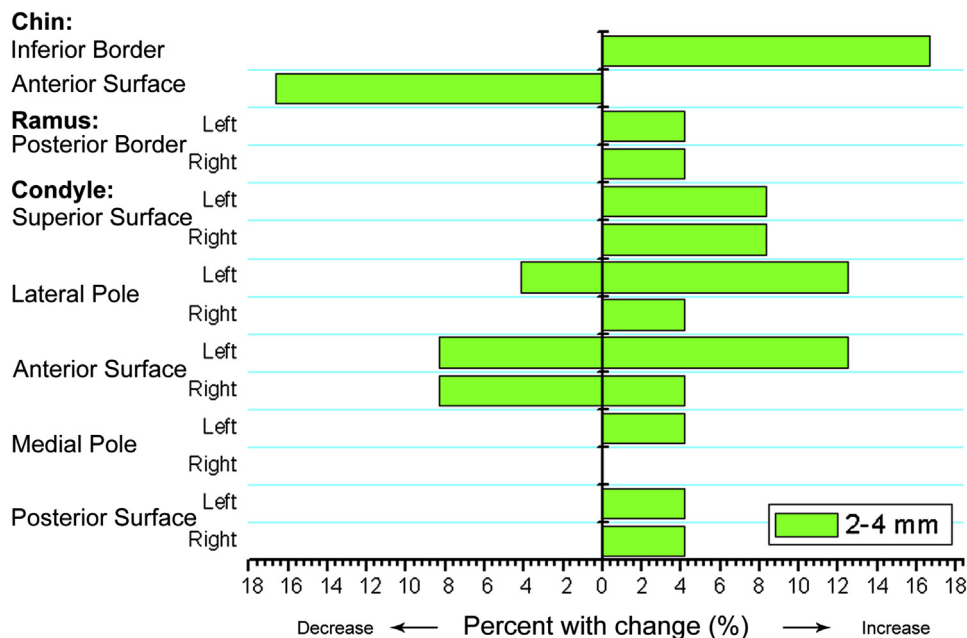


FIGURE 5. Percentage of patients with changes greater than 2 mm or less than -2 mm at 1- to 3-year follow-up. Patients with displacements of -2 to 2 mm are not represented. Positive or negative values of displacements represent different directional movements, depending on the specific region of interest. An *increase* was defined as anterior displacement for the anterior surface of the chin and anterior surface of the condyles but as posterior displacement for the posterior surface of the ramus and condyles and as inferior displacement of the inferior border of the chin. A *decrease* was defined as anterior displacement of the posterior surface of the ramus and condyles, as posterior displacement on the anterior surface of the chin and anterior surface of the condyles, and as superior displacement of the inferior border of the mandible.

Franco et al. Long-Term Stability of Mandibular Advancement. *J Oral Maxillofac Surg* 2013.

Table 1. DESCRIPTIVE STATISTICS FOR GREATEST DISPLACEMENT OR BONE REMODELING AT EACH ANATOMIC REGION FROM BEFORE SURGERY TO 1 YEAR AFTER SURGERY AND FROM 1 TO 3 YEARS AFTER SURGERY

Region	Before to 1 yr After Surgery (mm)	1 to 3 yr After Surgery (mm)
Ramus		
Right posterior border of ramus	-0.32 ± 2.56	0.39 ± 1.16
Left posterior border of ramus	-0.44 ± 3.02	0.18 ± 1.32
Chin		
Horizontal (anterior surface)	5.48 ± 3.53	-0.63 ± 1.33
Vertical (inferior surface)	5.53 ± 3.49	1.16 ± 1.03
Condyle		
Right posterior surface	1.27 ± 1.75	0.29 ± 0.99
Left posterior surface	0.72 ± 1.28	0.15 ± 1.14
Right medial pole	0.17 ± 1.63	-0.26 ± 0.91
Left medial pole	0.42 ± 1.50	-0.11 ± 1.15
Right anterior surface	-1.50 ± 1.04	-0.46 ± 1.27
Left anterior surface	-1.43 ± 1.61	-0.34 ± 1.50
Right lateral pole	-0.61 ± 1.66	0.19 ± 1.02
Left lateral pole	-0.91 ± 1.80	0.26 ± 1.18
Right superior surface	0.95 ± 1.72	0.39 ± 1.26
Left superior surface	0.48 ± 1.26	0.33 ± 1.14

Note: Data are presented as mean \pm standard deviation.

Franco et al. Long-Term Stability of Mandibular Advancement. *J Oral Maxillofac Surg* 2013.

areas of interest were not statistically different from 0. The inferior border of the mandible was the only area that had a statistically significant average change. The 1.11-mm average change indicated inferior displacement of the chin.

Virtually all patients had greater than 2 mm of anterior movement of the chin at 1 year after surgery. Approximately 40% had greater than 4 mm anterior displacement of the anterior surface of the chin (Fig 4).

The greatest long-term displacements or bone remodeling in the condylar areas occurred at the anterior surfaces (21% of cases on the left side and 13%

on the right), superior surfaces (8% on the right and left sides), and the lateral condylar poles (17% of cases on the left side and 4% on the right; Fig 5).

Regarding changes in the chin area 1 to 3 years after surgery, 17% of cases presented inferior displacement and 17% of cases presented posterior displacement from 2 to 4 mm. Overbite changes greater than 1 mm were noted for 17% of cases and overjet changes greater than 1.5 mm were noted for 17% of cases. The posterior border of the ramus exhibited symmetric 4% displacement on the right and left sides, with lateral or rotational long-term adaptation of the ramus (Fig 5).

Discussion

A series of studies published since the 1990s based on data from the Dentofacial Program of the University of North Carolina^{5,6,12,13,19,20} categorized the stability of orthognathic surgical procedures for different dentofacial disharmonies using 2-dimensional superimpositions or cephalometric measurements at different time points. Those studies provided parameters for orthodontists and oral and maxillofacial surgeons for decision making in the treatment of skeletal malocclusions involving the maxilla and mandible. In 2007, Proffit et al²⁰ updated the hierarchy of orthognathic surgical stability with follow-up to 5 years after surgery and stressed the importance of long-term assessment of surgical orthodontic procedures. The present study quantified 3D surgical displacements and bone remodeling 1 to 3 years after mandibular advancement surgery.

A fully automated voxel-wise registration of cranial base 3D superimposition has recently been applied to assess the stability of dental, skeletal, and soft tissue alterations 1 year after jaw surgery.^{1,7-12,17} The works of Carvalho et al¹⁰ and Motta et al¹ cannot be directly compared with the present study, because one third of the sample at 1-year follow up did not return for long-term assessments and other patients had been recruited and added to the sample. The 3D image analysis methods in the present study also focused on additional anatomic regions of interest to better evaluate local bone remodeling changes on the condylar surfaces and inferior border of the mandible.

In these short-term studies^{1,10} the chin position changed from splint removal to 1 year after surgery. Recorded changes indicated forward movement by at least 2 mm in 5 cases (19%) and relapse (displacement, ≤ -2 mm) in 7 cases (26%). In addition, the posterior border of the ramus exhibited at least 2-mm posterior displacement in 6 rami and anterior displacement in 2 (n = 54). In the present study, 4 patients (17% of cases) had at least 2-mm downward rotation of the inferior border of the mandible and posterior displacement of the

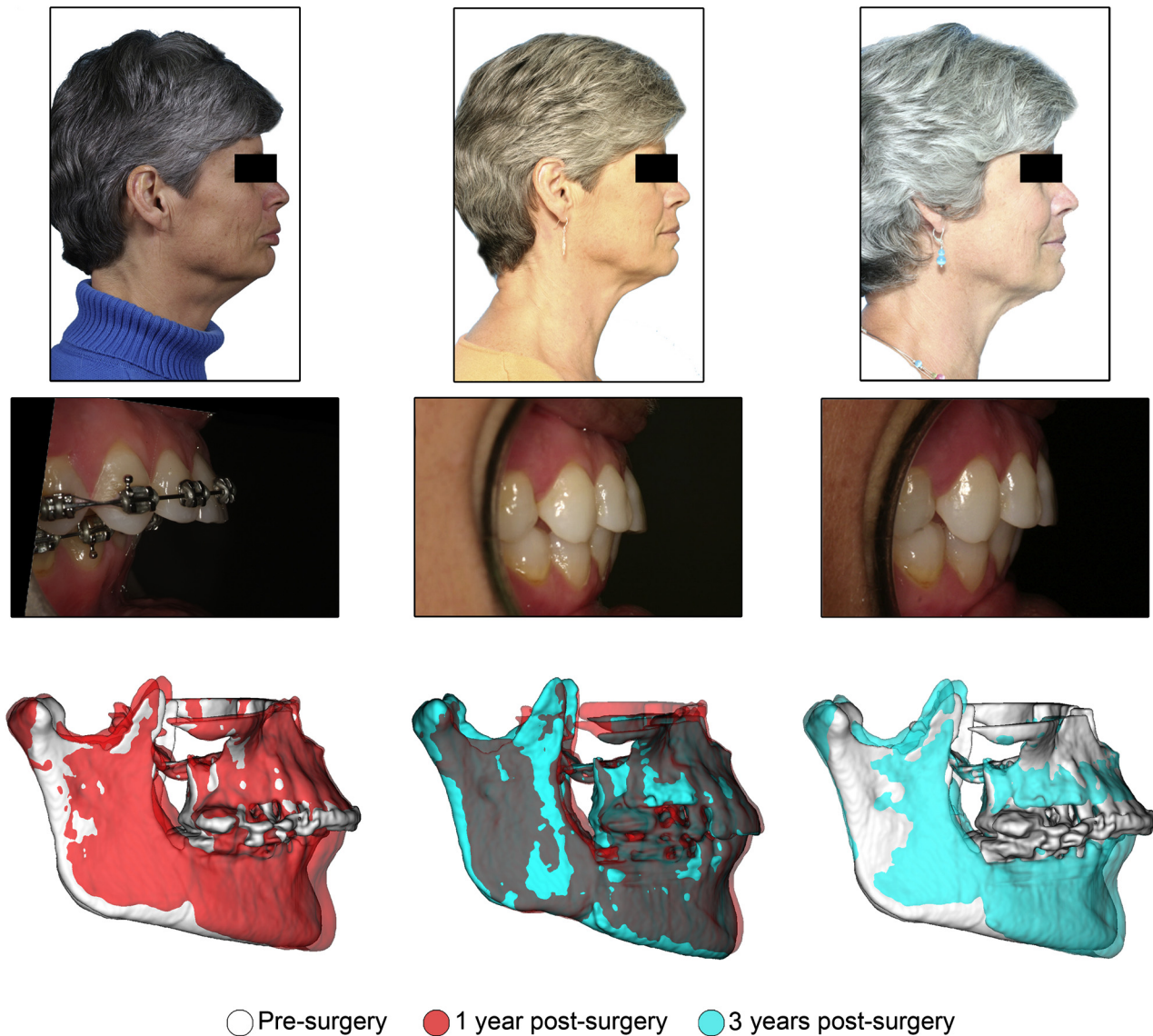


FIGURE 6. Facial profiles (*top*) and intraoral photographs (*middle*) of a patient who exhibited stability of mandibular advancement after comparison of presurgical, 1-year postsurgical, and 3-year postsurgical 3-dimensional models. *Bottom*, Lateral views of semitransparent superimpositions. Small changes in chin position were observed 1 to 3 years after surgery, and the condylar position and morphology remained stable.

Franco et al. Long-Term Stability of Mandibular Advancement. J Oral Maxillofac Surg 2013.

anterior surface of the chin, with partial relapse of the amount of mandibular advancement 1 to 3 years after surgery. Overbite changes for these patients were greater than 1 mm and overjet changes were greater than 1.5 mm, because partial dental compensation occurred to the observed skeletal changes. Only 1 patient (4%) presented with at least 2-mm bilateral posterior rotation of the ramus during this interval.

Carvalho et al¹⁰ reported that, from the immediate postsurgical period to 1-year follow-up for 27 patients treated with mandibular advancement (54 condyles), 3 condyles exhibited at least 2-mm anterior-inferior displacement and 6 condyles had posterior-superior displacement. The present study found that small condylar changes continue to occur beyond the first year

after surgery, with a variable direction of changes: at 1- to 3-year postsurgical follow-up of 24 patients (48 condyles), 4 condyles presented changes of at least 2 mm, indicative of anterior displacements or bone apposition, and 4 condyles exhibited changes no greater than -2 mm, indicative of posterior displacements or bone resorption on the anterior surface of the condyle. Four condyles also presented at least 2-mm superior displacement as shown in the patient in [Figures 7 and 9](#), and 4 condyles presented at least 2-mm lateral displacement or bone apposition in the lateral poles, leading to changes in condylar torque in relation to the ramus.

In summary, results of the present study indicate that, over the 3-year period, mandibular advancement surgery was, on average, stable, which corroborates

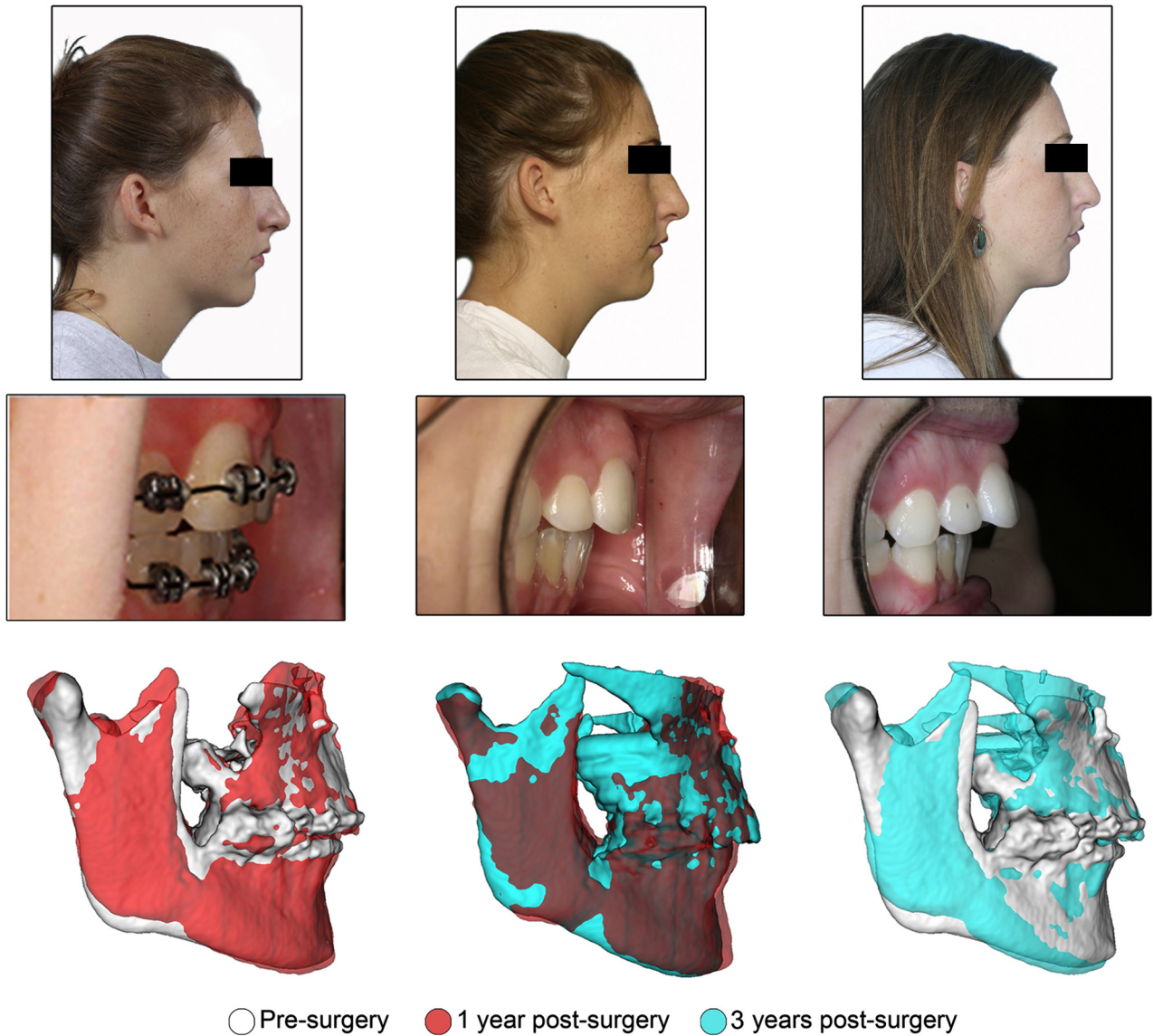


FIGURE 7. Facial profiles (top) and intraoral photographs (middle) of a patient who exhibited stability of mandibular advancement after comparison of presurgical, 1-year postsurgical, and 3-year postsurgical models. Bottom, Lateral views of skeletal semitransparent superimpositions. At 1 year after surgery, the chin advancement had returned to its original position. From 1 to 3 years after surgery, downward and backward displacement of the mandible progressed, compromising the surgical outcome.

Franco et al. Long-Term Stability of Mandibular Advancement. J Oral Maxillofac Surg 2013.

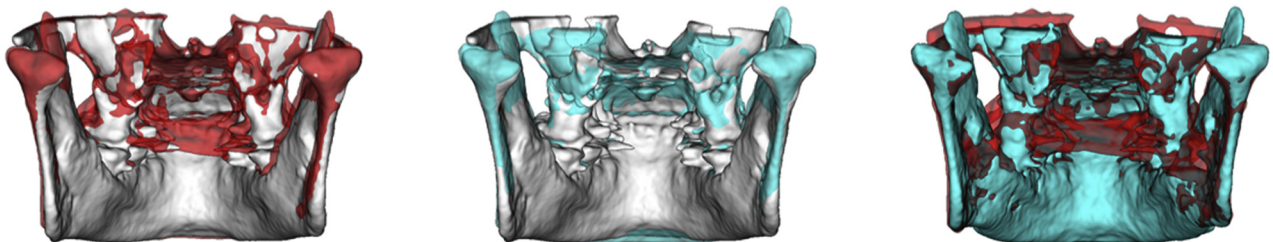


FIGURE 8. Posterior view of semitransparent superimpositions of patient shown in Figure 6. Overlays of presurgical (white), 1-year postsurgical (red), and 3-year postsurgical (blue) surface models are displayed. Note the stability of the condylar position and morphology during long-term follow-up.

Franco et al. Long-Term Stability of Mandibular Advancement. J Oral Maxillofac Surg 2013.

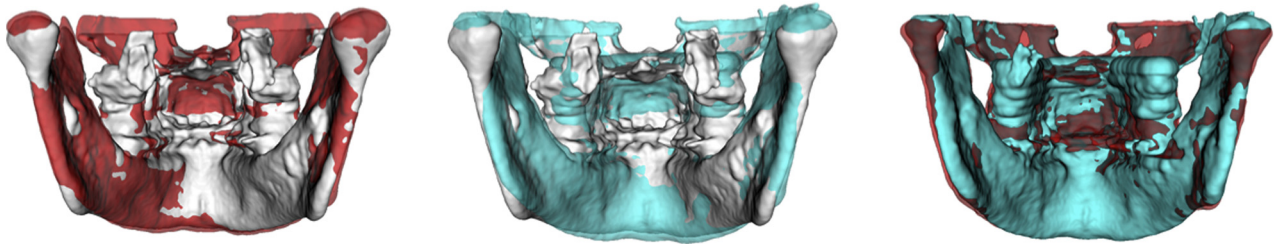


FIGURE 9. Posterior view of semitransparent superimpositions of patient shown in Figure 7. Overlay of presurgical (white) and 1-year postsurgical (red) surface models shows superior displacement and bone remodeling of the condyles. Overlay of presurgical (white) and 3-year postsurgical (blue) surface models shows superior displacement and further bone remodeling of the condyles. Overlay of 1-year (red) and 3-year (blue) postsurgical surface models shows the progression of bone remodeling in the condyles.

Franco et al. Long-Term Stability of Mandibular Advancement. *J Oral Maxillofac Surg* 2013.

findings from previous studies.^{5,6,20-22} However, at least 2-mm downward and backward rotation of the chin and condylar displacement or remodeling adaptive changes were observed in 17% of patients. Previous studies have questioned whether condylar displacements or remodeling after orthognathic surgery might cause temporomandibular disorders or relapse-related displacements.²³⁻²⁸ Draenert et al²⁹ emphasized that, although the condylar position might change after surgery, the treatment results do not alter the clinical characteristics of the temporomandibular joints, although symptoms might worsen in patients al-

ready exhibiting temporomandibular disorders before surgery.

The 3D analysis of CBCT images in this study provides additional information regarding bone remodeling and positional changes after mandibular advancement compared with traditional cephalometric methods. In this study, to measure distances between the bone surfaces at 2 time points, the closest surface point method was used. Current open-source and commercially available software packages (Geomagic Studio, Geomagic US Corp, Research Triangle Park, NC; Vultus, 3dMD, Atlanta, GA) calculate the closest points between 2 surfaces that are displaced with treatment. Quantification of surface distances by using closest points requires careful interpretation and comparisons with the semitransparent overlays to determine areas of bone remodeling versus displacement (Figs 8, 9), because closest point distances do not quantify vectorial magnitudes of 3D displacements and the closest points might not be homologous on the 2 surfaces. Therefore, when changes over time are of interest, quantification with isolines provides absolute positive or negative values of displacement and aids the assessment of the direction of displacement.

The present study indicates that 1 to 3 years after surgery, approximately 1 of 6 patients who have mandibular advancement surgery will show clinical changes (2 to 4 mm) in the horizontal and vertical chin positions. On average, small changes will occur in the condylar position and adaptive bone remodeling.

Table 2. ADJUSTED MEAN CHANGE FROM 1 YEAR TO 3 YEARS AFTER SURGERY

Region	Adjusted Mean \pm SE (mm)	P Value
Ramus		
Right posterior border of ramus	0.38 \pm 0.31	.23
Left posterior border of ramus	0.12 \pm 0.34	.72
Chin		
Horizontal (anterior surface)	-0.42 \pm 0.32	.20
Vertical (inferior surface)	1.11 \pm 0.22	<.0001
Condyle		
Right posterior surface	0.19 \pm 0.26	.47
Left posterior surface	0.02 \pm 0.28	.95
Right medial pole	-0.19 \pm 0.21	.38
Left medial pole	-0.07 \pm 0.30	.81
Right anterior surface	-0.32 \pm 0.33	.34
Left anterior surface	-0.27 \pm 0.33	.43
Right lateral pole	0.29 \pm 0.25	.27
Left lateral pole	0.34 \pm 0.30	.26
Right superior surface	0.12 \pm 0.29	.70
Left superior surface	0.19 \pm 0.30	.54

Abbreviation: SE, standard error.

Franco et al. Long-Term Stability of Mandibular Advancement. *J Oral Maxillofac Surg* 2013.

References

1. Motta AT, Cevidanes LH, Carvalho FA, et al: Three-dimensional regional displacements after mandibular advancement surgery: One year of follow-up. *J Oral Maxillofac Surg* 69:1447, 2011
2. Trauner R, Obwegeser H: The surgical correction of mandibular prognathism and retrognathia with consideration of genioplasty. I. Surgical procedures to correct mandibular prognathism and reshaping of the chin. *Oral Surg Oral Med Oral Pathol* 10:677, 1957
3. Dal Pont G: Retromolar osteotomy for the correction of prognathism. *J Oral Surg Anesth Hosp Dent Serv* 19:42, 1961

4. Proffit WR, Phillips C, Douvartzidis N: A comparison of outcomes of orthodontic and surgical-orthodontic treatment of Class II malocclusion in adults. *Am J Orthod Dentofacial Orthop* 101:556, 1992
5. Proffit WR, Turvey TA, Phillips C: Orthognathic surgery: A hierarchy of stability. *Int J Adult Orthod Orthognath Surg* 11:191, 1996
6. Bailey LJ, Proffit WR, White R Jr: Assessment of patients for orthognathic surgery. *Semin Orthod* 5:209, 1999
7. Cevidanes LH, Bailey LJ, Tucker SF, et al: Three-dimensional cone-beam computed tomography for assessment of mandibular changes after orthognathic surgery. *Am J Orthod Dentofac Orthop* 131:44, 2007
8. Cevidanes LH, Oliveira AE, Grauer D, et al: Clinical application of 3D imaging for assessment of treatment outcomes. *Semin Orthod* 17:72, 2011
9. Cevidanes LH, Franco AA, Gerig G, et al: Assessment of mandibular growth and response to orthopedic treatment with 3-dimensional magnetic resonance images. *Am J Orthod Dentofac Orthop* 128:16, 2005
10. Carvalho Fde A, Cevidanes LH, da Motta AT, et al: Three-dimensional assessment of mandibular advancement 1 year after surgery. *Am J Orthod Dentofac Orthop* 137(suppl):S53.e1, 2010
11. Almeida RC, Cevidanes LH, Carvalho FA, et al: Soft tissue response to mandibular advancement using 3D CBCT scanning. *Int J Oral Maxillofac Surg* 40:353, 2011
12. Bailey LJ, Cevidanes LH, Proffit WR: Stability and predictability of orthognathic surgery. *Am J Orthod Dentofac Orthop* 126:273, 2004
13. Proffit WR, Phillips C, Turvey TA: Long-term stability of adolescent versus adult surgery for treatment of mandibular deficiency. *Int J Oral Maxillofac Surg* 39:327, 2010
14. Epker BN: Modifications in the sagittal osteotomy of the mandible. *J Oral Surg* 35:157, 1977
15. Bell WH, Jacobs JD: Combined orthodontic-surgical correction of moderate mandibular deficiency. *Am J Orthod* 75:481, 1979
16. Yushkevich PA, Piven J, Hazlett HC, et al: User-guided 3D active contour segmentation of anatomical structures: Significantly improved efficiency and reliability. *Neuroimage* 31:1116, 2006
17. Cevidanes LH, Styner MA, Proffit WR: Image analysis and superimposition of 3-dimensional cone-beam computed tomography models. *Am J Orthod Dentofac Orthop* 129:611, 2006
18. Chapuis J, Schramm A, Pappas I, et al: A new system for computer-aided preoperative planning and intraoperative navigation during corrective jaw surgery. *IEEE Trans Inf Technol Biomed* 11:274, 2007
19. Simmons KE, Turvey TA, Phillips C, et al: Surgical-orthodontic correction of mandibular deficiency: Five-year follow-up. *Int J Adult Orthod Orthognath Surg* 7:67, 1992
20. Proffit WR, Turvey TA, Phillips C: The hierarchy of stability and predictability in orthognathic surgery with rigid fixation: An update and extension. *Head Face Med* 3:21, 2007
21. Miguel JA, Turvey TA, Phillips C, et al: Long-term stability of two-jaw surgery for treatment of mandibular deficiency and vertical maxillary excess. *Int J Adult Orthod Orthognath Surg* 10:235, 1995
22. Watzke IM, Turvey TA, Phillips C, et al: Stability of mandibular advancement by sagittal osteotomy with screw and wire fixation: A comparative study. *J Oral Maxillofac Surg* 48:108, 1990
23. Ow A, Cheung LK: Bilateral sagittal split osteotomies versus mandibular distraction osteogenesis: A prospective clinical trial comparing inferior alveolar nerve function and complications. *Int J Oral Maxillofac Surg* 39:756, 2010
24. Ow A, Cheung LK: Bilateral sagittal split osteotomies and mandibular distraction osteogenesis: A randomized controlled trial comparing skeletal stability. *Oral Surg Oral Med Oral Pathol Oral Radiol Endod* 109:17, 2010
25. De Clercq CA, Neyt LF, Mommaerts MY, et al: Condylar resorption in orthognathic surgery: A retrospective study. *Int J Adult Orthod Orthognath Surg* 9:233, 1994
26. Hwang SJ, Haers PE, Zimmermann A, et al: Surgical risk factors for condylar resorption after orthognathic surgery. *Oral Surg Oral Med Oral Pathol Oral Radiol Endod* 89:542, 2000
27. You MS, Yang HJ, Hwang SJ: Postoperative functional remodeling of preoperative idiopathic condylar resorption: A case report. *J Oral Maxillofac Surg* 69:1056, 2011
28. Kobayashi T, Izumi N, Kojima T, et al: Progressive condylar resorption after mandibular advancement. *Br J Oral Maxillofac Surg* 50:176, 2011
29. Draenert FG, Erbe C, Zenglein V, et al: 3D analysis of condylar position after sagittal split osteotomy of the mandible in mono and bimaxillary orthognathic surgery—A methodology study in 18 patients. *J Orofac Orthop* 71:421, 2010