

Facilitating Direct Bonding for Lingual Retainers

By Leonardo Koerich, DDS, MS; Antônio Carlos de Oliveira Ruellas, DDS, MS, PhD

Abstract: Directly bonded lingual retainers are not always easy because the available techniques do not keep the wire totally stable in position and there is risk of moist contamination. Indirect methods help to keep a moist-free environment and reduce chair time but have other drawbacks, such as lack of control over the composite placement leading to adhesive-tooth failure or undesirable flow of adhesive to gingival embrasures. The purpose of this report is to show a direct bonding method, helped by a laboratory made acrylic guide, which has benefits of direct and indirect techniques.

Keywords: Retainer Bonding

Introduction

Lingual retainers can be bonded either directly or indirectly. Techniques that aim to help position the wire in the correct place before adding and curing the composite have been reported in the literature.¹⁻³ If the wire is not fully stable in position before bonding, time will be required to correct it and there is a higher likelihood it will fail. The most common reason for failure is moisture contamination,⁴ which is related to early breakage.⁵ Indirect techniques have the benefit of keeping the surface dry; however, Karaman⁶ suggested that tooth-adhesive interface might not bond correctly, leading to failure. Another problem is that composite could flow towards the gingival embrasures⁶ because there is little control after placing the tray and compressing it against the teeth to light-cure. The purpose of this report is to show a direct method that uses a laboratory made acrylic guide to bond a lingual retainer that has benefits of both direct and indirect technique.

Case Report

After completion of treatment and before removal of the brackets, an alginate impression is taken. An 0.028 inch round stainless steel wire is bent from canine to canine and held in the correct position by a piece of wax at each of the cuspids. The wire should contact 2 different points (one distal and one mesial) on each of the incisors to avoid rotation. Next, warm wax is placed on the canines and part of the lateral

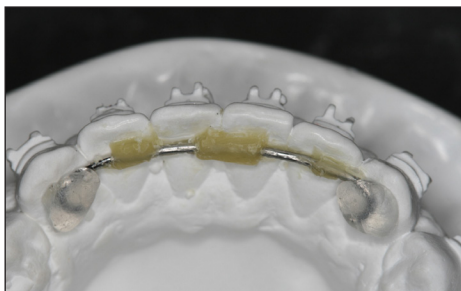


Figure 1 – Wire well adapted before and after placing the wax.

incisors to firmly hold the wire in position during the acrylic polymerization (Figure 1). Separating agent is placed on the model before construction of the acrylic stint. The acrylic addition was done using the sprinkle-on technique; however, the doughing technique seems to work as well. Excess should be removed during the early stages of polymerization, especially at the incisors brackets area, to avoid mechanical retention and to facilitate the separation later (Figure 2). After complete polymerization, the acrylic is removed in one piece with the wire and wax from the dental cast. The wax is cleaned and the excess acrylic is trimmed the excess (Figure 3). The wire should go in and out of the acrylic without much effort, with a “click” sound heard when it is placed. The stint should be positioned again on the dental cast to confirm the original wire position (Figure 4). Attention is required because the wire can slide within the groove.

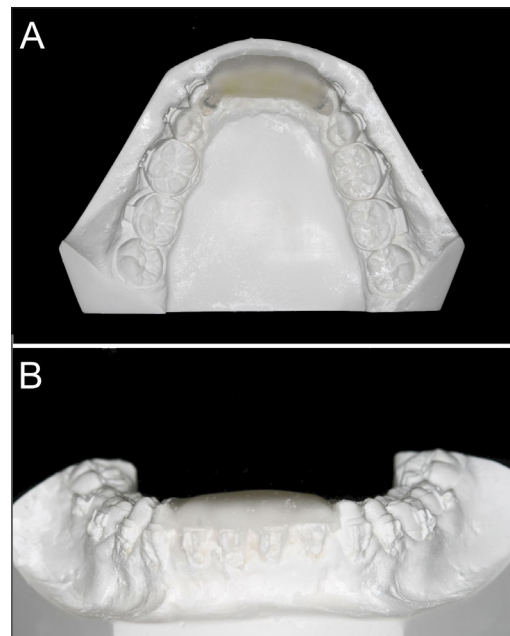


Figure 2 – Guide after polymerization. Notice the excess was removed during early stages of polymerization to avoid mechanical retention.

When the guide is placed on the patients' teeth, it should be exactly in the same position as it was on the model. After confirmation, the guide is removed and the regular steps to bond are taken. The lingual surfaces of the lower incisors are cleaned with pumice paste, etched with phosphoric acid for 30 seconds, rinsed,

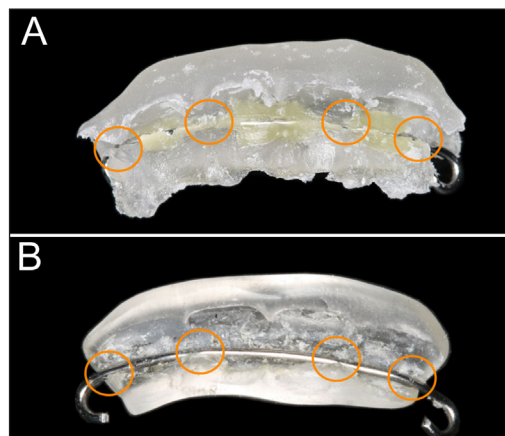


Figure 3 – Guide before and after being trimmed. Oranges circles shows points of retention of the wire and the acrylic stint.

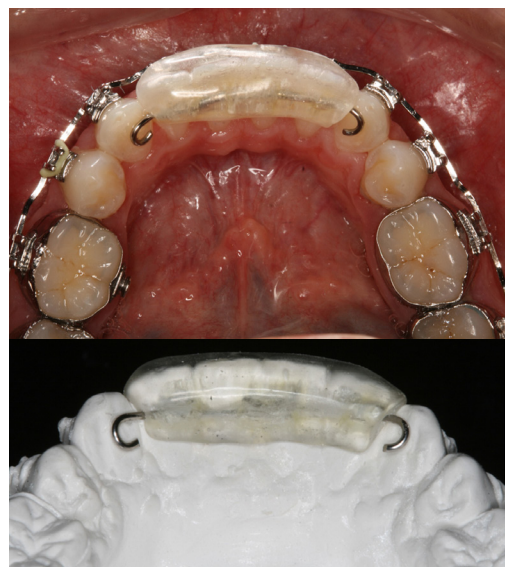


Figure 4 – Checking the position in the dental cast.

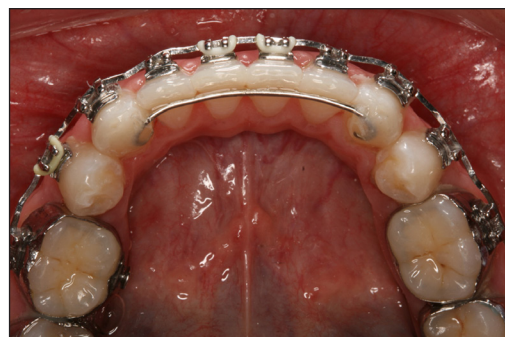

Figure 5 – Checking the position in patient's mouth before place the composite and after finish it.

dried, primer placed and light cured. The guide is placed and held with finger pressure and the composite of choice is applied to the canines and light cured (Figure 5).

Discussion

The technique described here for direct-guided retainer bonding could also be modified for different purposes. The wire used is a 0.028" stainless steel, however, the same could be done with a 0.0215" coaxial stainless steel wire, as it is the most used.¹ Modifications are required because this wire is more flexible and could deform plastically during the guide removal. The groove where the wire is place should be less retentive.

If it is desired to bond each of the incisors, this can be easily done after removing the guide. The wire will be firmly bonded on the canines and the clinician does not need to worry about undesirable wire position changes.

Some of the advantages are 1) reduced chair time, 2) because of the decreased amount of time needed to bond, it is easier to keep the dental surface moist-free, 3) the hardness of the acrylic will allow only one position for the wire, therefore the clinician has better precision with the wire placement, 4) because the composite is placed directly, there is less need to worry about adhesive or composite leakage leading to hygiene problems and 5) facilitates two-handed placement of a lingual retainer. The main disadvantage is the increased laboratory time.

Conclusion


This simple technique demonstrated presents advantages of both indirect and direct bonding methods, aiming to reduce the chair time and potentially decrease bond failure by avoiding contamination of the surface.

Acknowledgement

The authors would like to thanks Dr. Lindsey Eidson Koerich for the English review.

References

1. Bearn DR. Bonded orthodontic retainers: a review. *Am J Orthod Dentofacial Orthop.* 1995;108(2):207-13.
2. Meyers CE, Jr., Vogel S. Stabilization of retainer wire for direct bonding. *J Clin Orthod.* 1982;16(6):412.
3. Zachrisson BU. Clinical experience with direct-bonded orthodontic retainers. *Am J Orthod.* 1977;71(4):440-8.
4. Graber LW, Vanarsdall RL, Vig KWL. Orthodontics : current principles and techniques. 5th ed. Philadelphia, PA: Elsevier/Mosby; 2012.
5. Lumsden KW, Saidler G, McColl JH. Breakage incidence with direct-bonded lingual retainers. *Br J Orthod.* 1999;26(3):191-4.
6. Karaman AI, Polat O, Buyukyilmaz T. A practical method of fabricating a lingual retainer. *Am J Orthod Dentofacial Orthop.* 2003;124(3):327-30.



Dr. Leonardo Koerich is in the International Dental Program at Virginia Commonwealth University, USA. He completed his Post-doc Research Fellow, University of North Carolina - Chapel Hill and Master's in Orthodontics, Federal University of Rio de Janeiro, Brazil.



Dr. Antônio Carlos de Oliveira Ruellas is an Associate Professor, Department of Orthodontics and Pediatric Dentistry, School of Dentistry, Federal University of Rio de Janeiro, Rio de Janeiro, Brazil. Post-doc Research Fellow University of Michigan.